



Clinical and Radiological Pattern of Diabetic Foot Ulcers and Factors Associated with Amputation: A Hospital-Based Cross-Sectional Study.

Dr. Sabavat Laxmi Kalyani^{1*}, Dr. Supraja Jonnalagadda¹, Dr. Dharavath Gouthami¹, Dr. R. Tejashwini¹
¹Assistant Professor, Department of General Surgery, Government Medical College, Suryapet, Telangana, India

Page | 1

Abstract

Background:

Diabetic foot ulcers are among the most disabling complications of diabetes mellitus and remain a major cause of hospitalization, infection, and non-traumatic lower limb amputation. Clinical evaluation and radiological assessment together help define ulcer severity, detect underlying bone involvement, and identify patients at higher risk of limb loss.

Objectives:

To evaluate the clinical and radiological patterns of diabetic foot ulcers and to identify factors associated with lower limb amputation among patients attending a tertiary care teaching hospital.

Methods:

This hospital-based cross-sectional observational study was conducted at Government Medical College, Suryapet, Telangana, from January 2024 to December 2024. A total of 100 consecutive eligible patients with diabetic foot ulcers were enrolled after applying predefined inclusion and exclusion criteria. Demographic profile, duration of diabetes, glycaemic status, ulcer site, Wagner grade, neuropathy, peripheral arterial disease, infection, and radiographic findings were recorded. Factors associated with amputation were analyzed using descriptive comparison.

Results:

Most patients were aged 51–60 years, and males were predominant. A duration of more than 10 years was observed in half of the study population, and poor glycaemic control was common. Toe and forefoot ulcers accounted for most lesions. Grade 3 ulcers were the largest subgroup. Peripheral neuropathy and clinical infection were frequent findings. Radiological assessment most often showed soft tissue swelling and osteomyelitis. Lower limb amputation occurred in 26 patients and was more frequent in those with higher Wagner grade, osteomyelitis, peripheral arterial disease, infection, long-standing diabetes, and poor glycaemic control.

Conclusion:

Diabetic foot ulcers in this cohort were characterized by advanced ulcer grade, frequent neuropathy, significant infectious burden, and substantial radiological evidence of osteomyelitis. Patients with severe ulcers, vascular compromise, and poor metabolic control showed a higher proportion of amputation.

Recommendations:

Early recognition, prompt imaging, aggressive infection control, vascular evaluation, and multidisciplinary management are essential to improve limb salvage.

Keywords: Diabetic foot ulcer, osteomyelitis, peripheral neuropathy, Wagner grading, amputation, radiology

Submitted: December 17, 2026 **Accepted:** February 22, 2026 **Published:** March 30, 2026

Corresponding Author: Dr. Sabavat Laxmi Kalyani

Email: laxmikalyani.mims@gmail.com

Assistant Professor, Department of General Surgery, Government Medical College, Suryapet, Telangana, India



Student's Journal of Health Research Africa

e-ISSN: 2709-9997, p-ISSN: 3006-1059

Vol.7 No. 3 (2025): March 2026 Issue

<https://doi.org/10.51168/sjhrafrica.v7i3.2550>

Original Article

Introduction

Diabetes mellitus is a chronic metabolic disorder of increasing global concern, and its long-term complications continue to impose a substantial burden on patients, health systems, and surgical services [1-3]. Among these complications, diabetic foot ulceration is one of the most serious and costly manifestations because it frequently leads to infection, prolonged hospitalization, repeated procedures, and lower limb amputation [2,5,7]. The classical pathophysiological basis of diabetic foot disease includes peripheral neuropathy, peripheral arterial disease, foot deformity, repetitive unrecognized trauma, impaired wound healing, and superadded infection [2,3,5,8]. Wagner's seminal work also emphasized the close relationship between tissue destruction, infection, gangrene, and eventual amputation in diabetic feet.

The burden of diabetic foot ulcers extends beyond the local wound itself. Once ulceration develops, the risk of deep infection and osteomyelitis rises substantially, and the probability of hospital admission and amputation increases sharply [6,8,11]. Earlier epidemiological studies demonstrated that neuropathy, deformity, trauma, and vascular insufficiency are central determinants in the pathway leading to ulcer formation and limb loss [3,4]. Community-based data have further shown that new ulceration continues to occur in a clinically meaningful proportion of diabetic patients each year, underscoring the importance of preventive screening and risk stratification [4,9]. Because ulcer recurrence and progression remain common, diabetic foot disease is now recognized as a chronic, relapsing condition rather than an isolated event [2,12,13].

Clinical assessment remains the foundation of diabetic foot evaluation. Ulcer site, depth, grade, evidence of infection, sensory loss, and vascular insufficiency together shape prognosis and immediate management decisions [9,11]. Radiological assessment complements clinical examination by identifying soft tissue swelling, gas, cortical erosion, periosteal reaction, bone destruction, and joint involvement. Plain radiography continues to be the first-line imaging investigation when osteomyelitis is suspected, while advanced imaging is reserved for unresolved diagnostic questions or more complex disease [10,11,14]. Radiological evidence of bone involvement is especially relevant because diabetic foot osteomyelitis often changes the treatment pathway, the duration of antimicrobial therapy, and the likelihood of amputation.

Understanding the prevailing clinical and radiological patterns in a local tertiary care setting is important for improving triage, early diagnosis, and limb-salvage strategies. The objectives of the present hospital-based cross-sectional study were to evaluate the demographic profile, clinical characteristics, and radiological findings of diabetic foot ulcers and to identify factors associated with lower limb amputation among patients treated at Government Medical College, Suryapet, Telangana.

Methodology

Study design

The present study was a hospital-based cross-sectional observational study conducted to assess the clinical and radiological profile of diabetic foot ulcers and to examine the factors associated with lower limb amputation at a single point of hospital-based evaluation during the defined study period.

Place of study

The study was carried out at Government Medical College and associated teaching hospital, Suryapet, Telangana, a tertiary care government teaching institution providing specialist surgical and medical services to patients from Suryapet district and surrounding rural and semi-urban areas. The hospital receives patients with complicated diabetic foot disease requiring clinical assessment, radiological evaluation, wound care, debridement, infection control, and surgical decision-making, making it a relevant setting for studying diabetic foot ulcer severity and amputation-related factors.

Study period

Data were collected over 12 months from January 2024 to December 2024.

Study population and sample size

A total of 100 consecutive patients with diabetic foot ulcers were included in the final analysis. Consecutive sampling was used because the study was hospital-based and cross-sectional in design. The sample size was calculated using the single-proportion formula $n = Z^2p(1-p)/d^2$, where $Z = 1.96$ at 95% confidence level, $p = 50\%$ was used to obtain the maximum required sample in the absence of a reliable local estimate, and $d = 10\%$ was taken as the absolute precision. The calculated sample size was 96.04, which was rounded to 100 patients. Therefore, 100 eligible patients presenting



during the study period and satisfying the selection criteria were enrolled. The sample reflected the routine tertiary care case-mix encountered in the institution.

Eligibility criteria

Patients aged 18 years and above with a confirmed diagnosis of diabetes mellitus and a clinically identifiable foot ulcer were included. Patients with ulcers caused exclusively by acute trauma, non-diabetic etiologies, isolated venous ulcers, malignant ulcers, or incomplete clinical records were excluded from analysis.

Clinical assessment

A structured proforma was used to record age, sex, duration of diabetes, smoking history, associated hypertension, and glycaemic control. Poor glycaemic control was defined using HbA1c values above 8%. Detailed local examination of the foot documented the site of ulcer, presence of discharge or surrounding cellulitis, features suggestive of infection, sensory loss consistent with peripheral neuropathy, and evidence of peripheral arterial disease. Ulcers were graded according to the Wagner classification, a widely used system for stratifying lesion depth and gangrenous involvement [1]. Standard diabetic foot examination principles were followed in accordance with established foot risk assessment recommendations [9].

Radiological assessment

Plain radiographs of the affected foot were obtained for all study participants. Radiographs were evaluated for soft tissue swelling, osteomyelitis, cortical or trabecular bone destruction, periosteal reaction, soft tissue gas, and joint involvement. Plain X-ray was used as the first-line imaging modality because of its clinical utility, ready availability, and accepted role in the initial assessment of suspected diabetic foot osteomyelitis [11,14].

Outcome measure

The primary adverse outcome assessed in the study was lower limb amputation during the course of treatment. For analytic description, patients were grouped into amputation and no-amputation categories. Clinical and radiological variables were then compared between these groups to identify factors that showed a greater proportion among amputated patients.

Bias

Potential selection bias was minimized by enrolling consecutive eligible patients during the study period. Information bias was reduced by using a structured proforma for clinical variables and predefined criteria for ulcer grading, neuropathy, peripheral arterial disease, infection, and radiographic findings. Observer-related bias was addressed by documenting radiological findings from routine plain radiographs and by applying the same assessment approach across all participants. Confounding by diabetes duration, glycaemic control, vascular disease, infection, and ulcer grade was considered during descriptive comparison between amputation and no-amputation groups; however, residual confounding could not be eliminated because multivariable modelling was not performed.

Statistical analysis

Data were entered into a master sheet and analyzed using descriptive statistical methods. Categorical variables were expressed as frequency and percentage. Continuous variables available in the dataset, such as age, were expressed as mean and standard deviation where appropriate. Results were presented in structured tables to facilitate academic interpretation and journal presentation.

Ethical considerations

The study was conducted after obtaining institutional ethical clearance from the concerned authority of the Government Medical College, Suryapet. Written informed consent was obtained from all participants before enrolment and clinical/radiological evaluation. Patient confidentiality was maintained throughout data collection, analysis, and manuscript preparation by anonymizing all records. The study was performed in accordance with accepted ethical standards for observational clinical research.

Results

A total of 100 patients diagnosed with diabetic foot ulcers were included in this hospital-based cross-sectional study. The clinical presentation, radiological pattern, and factors associated with amputation were analyzed systematically. Demographic and diabetes-related characteristics of the study participants are summarized in Table 1.

Participant flow

During the study period, patients presenting with diabetic foot ulcers were assessed according to predefined eligibility

criteria. Patients with ulcers due exclusively to acute trauma, non-diabetic etiologies, isolated venous ulcers, malignant ulcers, or incomplete clinical records were excluded at screening. The final analysis included 100 consecutive

eligible patients with diabetic foot ulcers. Separate numerical screening-log data for excluded patients were not available for reconstruction from the final dataset.

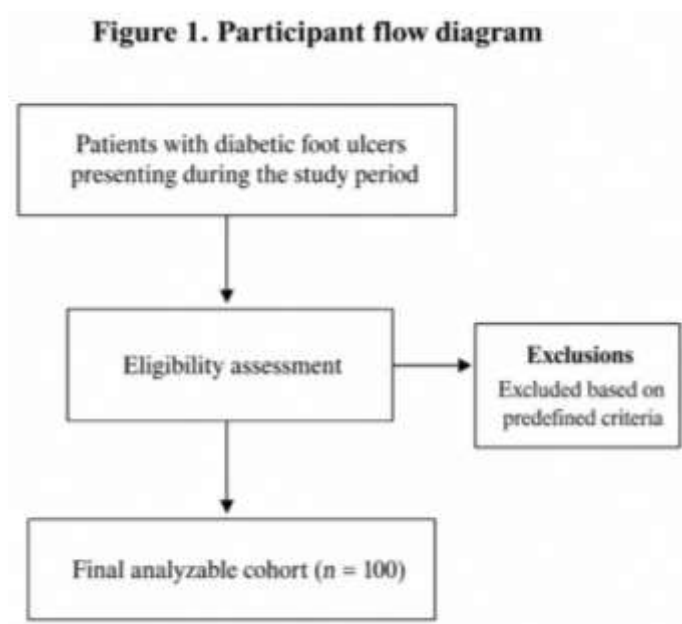


Figure 1. Participant flow



Table 1. Demographic and diabetes-related characteristics of study participants (n = 100)

Variable	Number	Percentage (%)
Age group (years)		
30–40	10	10.0
41–50	20	20.0
51–60	34	34.0
61–70	24	24.0
>70	12	12.0
Sex		
Male	66	66.0
Female	34	34.0
Duration of diabetes		
<5 years	14	14.0
5–10 years	36	36.0
>10 years	50	50.0
Poor glycaemic control (HbA1c >8%)	60	60.0
Hypertension	42	42.0
Smoking history	32	32.0

Most patients were in the 51–60 year age group (34%), followed by 61–70 years (24%). The mean age of the participants was 57.1 ± 10.8 years. Males constituted 66% of the study population, showing a male predominance. Half of the patients had diabetes for more than 10 years, and poor glycaemic control was present in 60% of the cohort.

The major clinical characteristics of diabetic foot ulcers, including site of ulceration, Wagner grading, neuropathy, peripheral arterial disease, and infection status, are shown in Table 2.



Table 2. Clinical characteristics of diabetic foot ulcers (n = 100)

Clinical parameter	Number	Percentage (%)
Site of ulcer		
Toes	32	32.0
Forefoot	30	30.0
Midfoot	16	16.0
Heel	22	22.0
Wagner grade of ulcer		
Grade 1	16	16.0
Grade 2	28	28.0
Grade 3	30	30.0
Grade 4	18	18.0
Grade 5	8	8.0
Peripheral neuropathy	64	64.0
Peripheral arterial disease	26	26.0
Clinical infection present	56	56.0

Toe involvement was the most common ulcer location (32%), followed closely by forefoot ulcers (30%). According to Wagner classification, Grade 3 ulcers were the most frequent (30%), followed by Grade 2 ulcers (28%).

Peripheral neuropathy was observed in 64% of patients, while peripheral arterial disease was identified in 26%. Clinical infection was present in 56% of cases, indicating a substantial burden of active local sepsis.

Table 3. Radiological findings in patients with diabetic foot ulcers (n = 100)

Radiological finding	Number	Percentage (%)
Normal radiograph	20	20.0
Osteomyelitis	38	38.0
Soft tissue swelling	54	54.0
Bone destruction	26	26.0
Periosteal reaction	18	18.0
Soft tissue gas	10	10.0
Joint involvement	8	8.0



Radiological evaluation demonstrated soft tissue swelling in 54% of patients, representing the most frequent imaging finding. Osteomyelitis was identified in 38% of cases, while bone destruction was observed in 26%. Periosteal reaction

was present in 18%, and soft tissue gas, a marker of severe infection, was detected in 10% of patients. Only one-fifth of the study population showed no abnormality on plain radiography.

Table 4. Factors associated with amputation among patients with diabetic foot ulcers (n = 100)

Factor	Amputation (n = 26) n (%)	No amputation (n = 74) n (%)
Wagner grade ≥ 3	20 (76.9)	36 (48.6)
Osteomyelitis	18 (69.2)	20 (27.0)
Peripheral arterial disease	14 (53.8)	12 (16.2)
Peripheral neuropathy	18 (69.2)	46 (62.2)
Clinical infection	22 (84.6)	34 (45.9)
Diabetes duration >10 years	17 (65.4)	33 (44.6)
Poor glycaemic control	19 (73.1)	41 (55.4)

Overall, 26% of patients required lower limb amputation. Higher proportions in the amputation group were observed for Wagner grade ≥ 3 ulcers (76.9%), osteomyelitis (69.2%), peripheral arterial disease (53.8%), clinical infection (84.6%), diabetes duration greater than 10 years (65.4%), and poor glycaemic control (73.1%). These findings indicate that advanced local disease, radiological evidence of bone infection, vascular insufficiency, and uncontrolled diabetes contributed importantly to adverse outcomes in this cohort.

Discussion

The present hospital-based cross-sectional study examined the clinical and radiological profile of diabetic foot ulcers in a tertiary care teaching hospital and assessed the factors associated with lower limb amputation. The overall profile of the study population reflected the typical burden of diabetic foot disease seen in hospital practice, with predominance among middle-aged and elderly men, long-standing diabetes, poor glycaemic control, and a high proportion of clinically significant infection. These findings are consistent with prior descriptions of diabetic foot ulcer populations in which neuropathy, vascular disease, and metabolic dysregulation interact to produce tissue loss and chronic wound complications [7,13].

Most patients in the present study were between 51 and 60 years of age, and males accounted for two-thirds of the cohort. Similar age clustering has been described in earlier epidemiological studies and reviews, which have shown that diabetic foot complications become more frequent with increasing age and longer duration of diabetes [4,9,13]. Half of the patients in the current series had diabetes for more than 10 years, and poor glycaemic control was common. This pattern is clinically important because chronic hyperglycaemia contributes to neuropathy, microvascular dysfunction, immune impairment, and delayed wound healing, thereby increasing susceptibility to infection and progression to deeper tissue destruction [2,7,11].

Toe and forefoot ulcers were the predominant anatomical sites in the present study. This distribution is biologically plausible and aligns with the known pressure-bearing nature of the forefoot and digital regions, where repetitive trauma, deformity, callus formation, and sensory loss create favorable conditions for ulceration [3,4,9]. The predominance of Grade 3 lesions and the combined frequency of Grade 3 to Grade 5 ulcers indicate that many patients reached tertiary care with already advanced disease. This late presentation mirrors the clinical reality described in diabetic foot literature, where delayed recognition and



Student's Journal of Health Research Africa

e-ISSN: 2709-9997, p-ISSN: 3006-1059

Vol.7 No. 3 (2025): March 2026 Issue

<https://doi.org/10.51168/sjhrafrica.v7i3.2550>

Original Article

Page | 8

inadequate early off-loading often allow progression from superficial ulceration to deep infection and gangrene [1,2,5]. Peripheral neuropathy was present in 64% of patients and clinical infection in 56%, emphasizing the central role of neuropathic injury and superadded sepsis in diabetic foot pathology. Peripheral arterial disease, although less frequent than neuropathy, affected over one-quarter of the cohort and showed a clear concentration in the amputation group. Earlier work by Pecoraro and colleagues, as well as later guideline-based reviews, established that ischemia and infection are major accelerants of limb loss once ulceration has occurred [6,8,11]. In the present study, these mechanisms were reflected in the higher proportions of amputation among patients with peripheral arterial disease and infected wounds.

Radiologically, soft tissue swelling and osteomyelitis were the leading abnormalities. This finding is important because plain radiography, although less sensitive than magnetic resonance imaging in early disease, remains the most practical first-line investigation in many hospitals and is specifically recommended in guideline-based diagnostic pathways [11,14]. Osteomyelitis in particular is clinically meaningful because it often prolongs treatment, increases the need for surgical intervention, and worsens limb salvage prospects [10-14]. In the present series, osteomyelitis was distinctly more common in amputated patients, reinforcing its value as a poor prognostic indicator. The concentration of Wagner grade ≥ 3 ulcers, clinical infection, osteomyelitis, poor glycaemic control, and long diabetes duration in the amputation group supports the concept that amputation is typically the result of multiple interacting risk factors rather than a single isolated variable.

Overall, the study highlights the need for early foot screening, tighter glycaemic control, prompt imaging for suspected bone involvement, vascular assessment, and coordinated multidisciplinary care. These measures remain central to limb preservation and are repeatedly emphasized across contemporary diabetic foot literature and consensus recommendations.

Generalizability

The findings are most applicable to tertiary care government teaching hospitals that manage patients with clinically significant diabetic foot ulcers from mixed rural and semi-urban populations. The predominance of advanced ulcer grade, infection, peripheral neuropathy, and radiological osteomyelitis may reflect referral patterns and delayed

presentation in similar resource-limited settings. Therefore, the results may be useful for comparable surgical units and diabetic foot clinics, although direct extrapolation to primary care, private outpatient practice, or community-screened diabetic populations should be made cautiously.

Conclusion

Diabetic foot ulcers in this study were most frequently seen in middle-aged and elderly patients with long-standing diabetes and poor glycaemic control. Toe and forefoot lesions, higher Wagner grades, peripheral neuropathy, infection, and radiological evidence of osteomyelitis formed the dominant clinical pattern. Amputation occurred in more than one-fourth of patients and was notably associated with severe ulcer grade, peripheral arterial disease, infection, osteomyelitis, and prolonged diabetes duration. These findings support the need for early risk identification, routine foot examination, prompt radiological evaluation, aggressive infection control, vascular assessment, and multidisciplinary management to reduce preventable limb loss in diabetic patients.

Limitations

The study was conducted in a single tertiary care center and included a moderate sample of 100 patients. Advanced imaging modalities such as MRI were not used uniformly for all participants. The analysis was descriptive and did not include multivariable statistical modeling. Separate numerical screening-log data for excluded patients were not available, limiting detailed reconstruction of participant flow. Follow-up beyond the index treatment period was not available, so long-term recurrence and functional outcomes were not assessed.

Recommendations

Routine diabetic foot screening should be integrated into all diabetes clinics, with particular attention to neuropathy, vascular insufficiency, deformity, and early skin breakdown. Patients should receive structured education on foot hygiene, footwear, glycaemic control, and prompt reporting of trauma or infection. Wagner grading and baseline radiography should be used early to identify deep tissue involvement and osteomyelitis. High-risk patients require timely surgical review, vascular assessment, culture-guided antibiotics, and regular wound care. A multidisciplinary limb-salvage approach involving surgeons, physicians, radiologists, podiatrists, and nursing



Student's Journal of Health Research Africa

e-ISSN: 2709-9997, p-ISSN: 3006-1059

Vol.7 No. 3 (2025): March 2026 Issue

<https://doi.org/10.51168/sjhrafrica.v7i3.2550>

Original Article

staff is strongly recommended to reduce progression, amputation rates, disability, and healthcare burden.

Acknowledgements

The authors sincerely acknowledge the support of the Department of General Surgery, Government Medical College, Suryapet, for providing the clinical facilities required for this study. They also thank the patients and hospital staff for their cooperation, assistance in data collection, and support throughout the conduct of the study.

List of Abbreviations

HbA1c: Glycated haemoglobin;
MRI: Magnetic resonance imaging;
PAD: Peripheral arterial disease.

Source of funding

The study has no funding

Conflict of interest

The author declares no conflict of interest.

Author contributions

SLK-Concept and design of the study, results interpretation, review of literature, and preparing the first draft of the manuscript. Statistical analysis and interpretation, revision of manuscript. **SJ-**Concept and design of the study, results interpretation, review of literature, and preparing the first draft of the manuscript, revision of the manuscript. **DG-**Review of literature and preparing the first draft of the manuscript. Statistical analysis and interpretation. **RT-**Design of the study, results interpretation, review of literature, and preparing the first draft of the manuscript, revision of the manuscript

Data availability

Data available on request

Author Biography

Dr. Sabavat Laxmi Kalyani is currently serving as an Assistant Professor at Government Medical College, Suryapet, Telangana, India. She completed her MBBS from Mediciti Institute of Medical Sciences and subsequently obtained her MS in General Surgery from Osmania Medical College, Hyderabad, Telangana, India. She further completed one year of Senior Residency at Government

Medical College, Mancherial, Telangana, India. In addition, she holds FISCIP [Fellowship of the International Society of Coloproctology]. Dr. Kalyani has three years of teaching experience and is actively involved in surgical education, clinical training, and academic activities. **ORCID ID:** <https://orcid.org/0009-0002-5061-023X>

Dr. Supraja Jonnalagadda is currently serving as an Assistant Professor at Government Medical College, Suryapet, Telangana, India. She completed her MBBS from Kasturba Medical College, Mangalore, and obtained her MS in General Surgery from Kamineni Institute of Medical Sciences, Narketpally. She subsequently completed her Senior Residency at Government Medical College, Suryapet. Dr. Jonnalagadda has three years of teaching experience and is actively involved in undergraduate medical education, surgical training, and academic activities. **ORCID ID:** <https://orcid.org/0009-0003-6328-4135>

Dr. Dharavath Gouthami is currently serving as an Assistant Professor at Government Medical College, Suryapet, Telangana, India. She completed her MBBS from Kakatiya Medical College, Warangal, and subsequently obtained her MS in General Surgery from the Upgraded Department of General Surgery, Osmania Medical College, Hyderabad. She also completed one year of Senior Residency at Osmania Medical College, Hyderabad. In addition, she holds FISCIP [Fellowship of the International Society of Coloproctology].

Dr. Gouthami has extensive clinical and academic experience. She worked for four years as a Specialist Surgeon at Singareni Collieries Company Limited, Bhupalpally, Warangal, where she gained substantial surgical expertise in patient care and management. She also has three years of teaching experience and is actively involved in undergraduate medical education, surgical training, and academic activities. **ORCID ID:** <https://orcid.org/0009-0009-4418-5522>

Dr. R. Tejashwini is currently serving as an Assistant Professor at Government Medical College, Suryapet, Telangana, India. She completed her MBBS from Kakatiya Medical College, Warangal, Telangana, India, and subsequently obtained her MS in General Surgery from Osmania Medical College, Hyderabad, Telangana, India. She also completed one year of Senior Residency at Rajiv Gandhi Institute of Medical Sciences, Adilabad. Dr. Tejashwini has three years of teaching experience and is actively engaged in medical education, surgical training, and



academic activities. ORCID ID: <https://orcid.org/0009-0003-7311-1203>

References

1. Wagner FW Jr. The diabetic foot. *Orthopedics*. 1987 Jan;10(1):163-72. <https://doi.org/10.3928/0147-7447-19870101-28>
2. Pecoraro RE, Reiber GE, Burgess EM. Pathways to diabetic limb amputation. Basis for prevention. *Diabetes Care*. 1990 May;13(5):513-21. <https://doi.org/10.2337/diacare.13.5.513>
3. Reiber GE, Vileikyte L, Boyko EJ, del Aguila M, Smith DG, Lavery LA, et al. Causal pathways for incident lower-extremity ulcers in patients with diabetes from two settings. *Diabetes Care*. 1999 Jan;22(1):157-62. <https://doi.org/10.2337/diacare.22.1.157>
4. Abbott CA, Carrington AL, Ashe H, Bath S, Every LC, Griffiths J, et al. The North-West Diabetes Foot Care Study: incidence of, and risk factors for, new diabetic foot ulceration in a community-based patient cohort. *Diabet Med*. 2002 May;19(5):377-84. <https://doi.org/10.1046/j.1464-5491.2002.00698.x>
5. Jeffcoate WJ, Harding KG. Diabetic foot ulcers. *Lancet*. 2003 May 3;361(9368):1545-51. [https://doi.org/10.1016/S0140-6736\(03\)13169-8](https://doi.org/10.1016/S0140-6736(03)13169-8)
6. Lipsky BA, Berendt AR, Deery HG, Embil JM, Joseph WS, Karchmer AW, et al. Diagnosis and treatment of diabetic foot infections. *Clin Infect Dis*. 2004 Oct 1;39(7):885-910. <https://doi.org/10.1086/424846>
7. Singh N, Armstrong DG, Lipsky BA. Preventing foot ulcers in patients with diabetes. *JAMA*. 2005 Jan 12;293(2):217-28. <https://doi.org/10.1001/jama.293.2.217>
8. Lavery LA, Armstrong DG, Wunderlich RP, Mohler MJ, Wendel CS, Lipsky BA. Risk factors for foot infections in individuals with diabetes. *Diabetes Care*. 2006 Jun;29(6):1288-93. <https://doi.org/10.2337/dc05-2425>
9. Boulton AJM, Armstrong DG, Albert SF, Frykberg RG, Hellman R, Kirkman MS, et al. Comprehensive foot examination and risk assessment: a report of the task force of the foot care interest group of the American Diabetes Association, with endorsement by the American Association of Clinical Endocrinologists. *Diabetes Care*. 2008 Aug;31(8):1679-85. <https://doi.org/10.2337/dc08-9021>
10. Berendt AR, Peters EJG, Bakker K, Embil JM, Eneroth M, Hinchliffe RJ, et al. Diabetic foot osteomyelitis: a progress report on diagnosis and a systematic review of treatment. *Diabetes Metab Res Rev*. 2008 May-Jun;24 Suppl 1:S145-61. <https://doi.org/10.1002/dmrr.836>
11. Lipsky BA, Berendt AR, Cornia PB, Pile JC, Peters EJG, Armstrong DG, et al. 2012 Infectious Diseases Society of America clinical practice guideline for the diagnosis and treatment of diabetic foot infections. *Clin Infect Dis*. 2012 Jun;54(12):e132-73. <https://doi.org/10.1093/cid/cis346>
12. Armstrong DG, Boulton AJM, Bus SA. Diabetic foot ulcers and their recurrence. *N Engl J Med*. 2017 Jun 15;376(24):2367-75. <https://doi.org/10.1056/NEJMra1615439>
13. Armstrong DG, Tan TW, Boulton AJM, Bus SA. Diabetic foot ulcers: a review. *JAMA*. 2023 Jul 3;330(1):62-75. <https://doi.org/10.1001/jama.2023.10578>
14. Senneville É, Albalawi Z, van Asten SA, Abbas ZG, Allison G, Aragón-Sánchez J, et al. Diagnosis of infection in the foot of patients with diabetes: a systematic review. *Diabetes Metab Res Rev*. 2024 Mar;40(3):e3723. <https://doi.org/10.1002/dmrr.3723>



Student's Journal of Health Research Africa
e-ISSN: 2709-9997, p-ISSN: 3006-1059
Vol.7 No. 3 (2025): March 2026 Issue
<https://doi.org/10.51168/sjhrafrica.v7i3.2550>
Original Article

PUBLISHER DETAILS:

Student's Journal of Health Research (SJHR)

(ISSN 2709-9997) Online

(ISSN 3006-1059) Print

Category: Non-Governmental & Non-profit Organization

Email: studentsjournal2020@gmail.com

WhatsApp: +256 775 434 261

Location: Scholar's Summit Nakigalala, P. O. Box 701432,
Entebbe Uganda, East Africa

